

Images in clinical medicine



Brugada syndrome unmasked by fever

 Yong Khai Pang,  Kian Seng Ng

Corresponding author: Yong Khai Pang, Department of Internal Medicine, International Medical University, Clinical Campus Kluang, Kluang, Johor, Malaysia. pangyongkhai@gmail.com

Received: 23 Oct 2022 - **Accepted:** 01 Jan 2023 - **Published:** 19 Jan 2023

Keywords: Fever, Brugada type 1, fainting spell, Brugada syndrome

Copyright: Yong Khai Pang et al. PAMJ Clinical Medicine (ISSN: 2707-2797). This is an Open Access article distributed under the terms of the Creative Commons Attribution International 4.0 License (<https://creativecommons.org/licenses/by/4.0/>), which permits unrestricted use, distribution, and reproduction in any medium, provided the original work is properly cited.

Cite this article: Yong Khai Pang et al. Brugada syndrome unmasked by fever. PAMJ Clinical Medicine. 2023;11(24). 10.11604/pamj-cm.2023.11.24.37959

Available online at: <https://www.clinical-medicine.panafrican-med-journal.com//content/article/11/24/full>

Brugada syndrome unmasked by fever

Yong Khai Pang^{1,&}, Kian Seng Ng¹

¹Department of Internal Medicine, International Medical University, Clinical Campus Kluang, Kluang, Johor, Malaysia

&Corresponding author

Yong Khai Pang, Department of Internal Medicine, International Medical University, Clinical Campus Kluang, Kluang, Johor, Malaysia

Image in medicine

A 32-year-old man presented with high fever, cough and sore throat. He was seen on the second day of his febrile illness after he experienced a “fainting spell”. He felt thumping in his chest and then fell into unconsciousness. Minutes later, he recovered spontaneously. His elder brother, aged 35 years had died of a “fast irregular heart rhythm”. Physical examination was unremarkable and his temperature was 39°C. An Electrocardiogram (ECG) was taken. The ECG manifests Brugada type 1 coved pattern in V1-V3 (A, B). There is a pseudo-right bundle branch block. At the end of QRS, there is an ST-segment elevation (STE) of ≥ 2 mm in V1 and V2. The STE is followed immediately by an oblique rectilinear downsloping ST which terminates in a small T wave inversion. Serial ECGs over 4 days showed

reversal of abnormalities with defervescence. On Day 3 (C), the temperature fell to 37.7°C and the Brugada type 1 covered pattern had evolved to the type 2 saddleback pattern. On the fifth and sixth day of his illness (D,E), the right precordial leads had normal morphology. Cardiac enzymes and electrolytes were normal. The history of a fever induced Brugada type 1 covered pattern, a probable

syncope, a brother who died of a tachyarrhythmia, the reversal of ECG abnormalities with defervescence pointed to the diagnosis of Brugada Syndrome. The patient was referred to the National Heart Centre where the diagnosis was confirmed and an automatic implantable cardiac defibrillator was implanted.

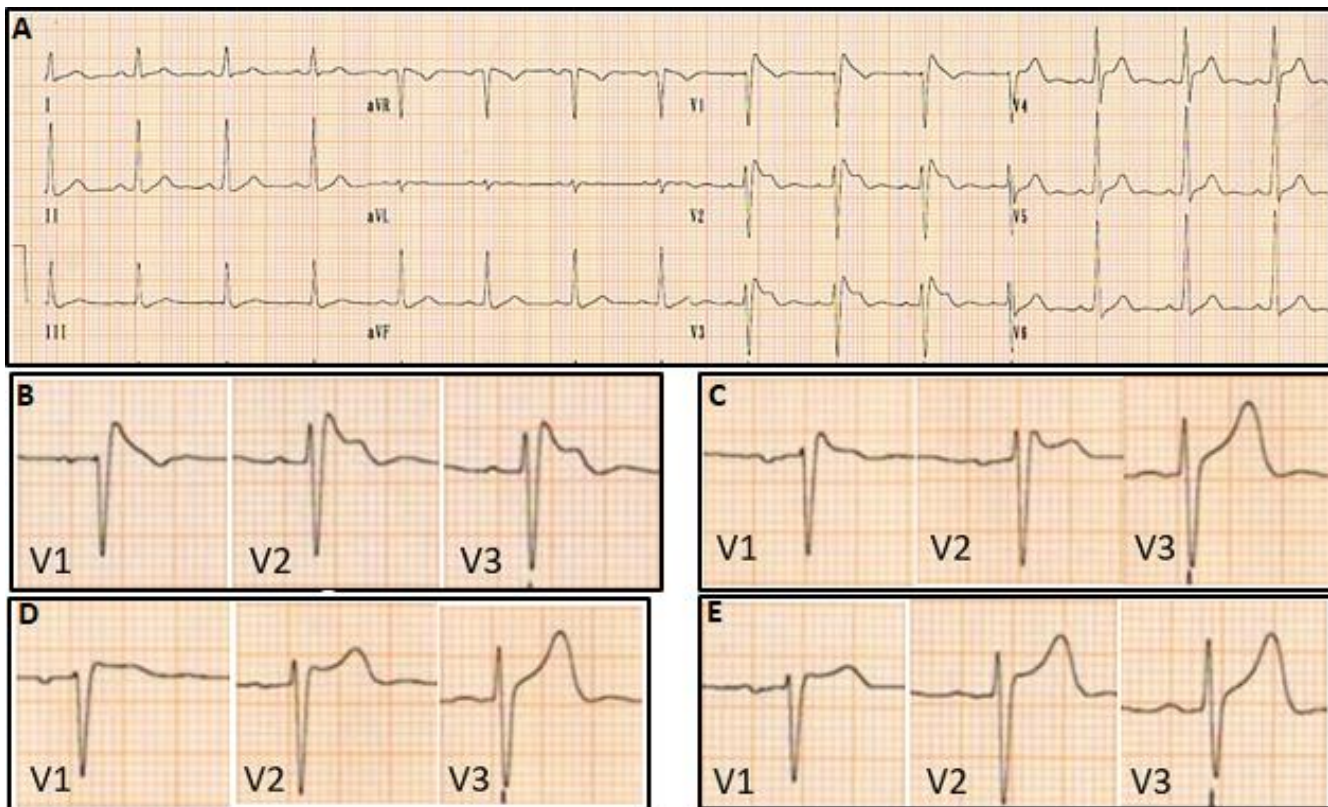


Figure 1: (A) 12 lead ECG of patient; leads V1 to V3 manifests Brugada type 1 covered pattern, pseudo-right bundle branch block, ST segment elevation of > 2mm; (B) day 2, temperature 39°C; (C) day 3, temperature 37.7°C; (D) day 4, temperature 37.1°C; (E) day 5, temperature 36.9°C; (B) to (E) leads V1 to V3 show Brugada type 1 covered pattern that reverses with defervescence; ECG was not taken on day 4