

Images in clinical medicine



An exceptional localization of hydatidosis

Oussama Eladaoui, Abdelhak Garch

Corresponding author: Oussama Eladaoui, Department of Traumatology and Orthopedic Surgery P32, University Hassan II, Morocco. oussamaeladaoui@gmail.com

Received: 23 Jun 2020 - **Accepted:** 03 Jul 2020 - **Published:** 14 Jul 2020

Keywords: Hydatidosis, huge, cyst

Copyright: Oussama Eladaoui et al. PAMJ Clinical Medicine (ISSN: 2707-2797). This is an Open Access article distributed under the terms of the Creative Commons Attribution International 4.0 License (<https://creativecommons.org/licenses/by/4.0/>), which permits unrestricted use, distribution, and reproduction in any medium, provided the original work is properly cited.

Cite this article: Oussama Eladaoui et al. An exceptional localization of hydatidosis. PAMJ Clinical Medicine. 2020;3(106). 10.11604/pamj-cm.2020.3.106.24529

Available online at: <https://www.clinical-medicine.panafrican-med-journal.com//content/article/3/106/full>

An exceptional localization of hydatidosis

Oussama Eladaoui^{1,&}, Abdelhak Garch¹

¹Department of Traumatology and Orthopedic Surgery P32, University Hassan II, Morocco

&Corresponding author

Oussama Eladaoui, Department of Traumatology and Orthopedic Surgery P32, University Hassan II, Morocco

Image in medicine

A 48-years-old woman, presenting a huge mass of the posterior surface of the thigh, fixed on the deep and superficial planes, evolving for 1 year. The patient has no particular pathological history, and no other signs were noted, including neither weight's loss nor general deterioration. The patient doesn't have any inguinal adenopathy or abdominal masses on the clinical examination, but she complains paresthesia in the popliteal sciatic nerve's territory. A biological report showed a hypereosinophyly, and MRI was performed, showing a septated cystic mass measuring 24 cm of the major axis, compressing the great sciatic nerve.

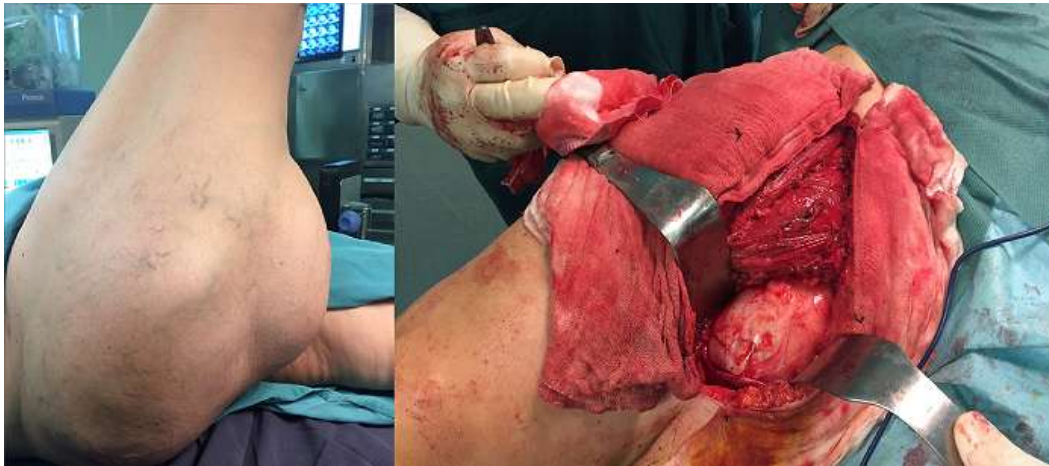


Figure 1: image of a huge hydatid cyst