

Images in clinical medicine



Amyand hernia with acute appendicitis: an exceptional case report

Mohammed Lamghari, Mohamed Bouzroud

Corresponding author: Mohammed Lamghari, Department of General Surgery, Military Hospital Mohammed V (HMIMV), Faculty of Medicine and Pharmacy, Mohammed V University, Rabat, Morocco. lamgharimohammed90@gmail.com

Received: 15 Jun 2020 - **Accepted:** 24 Jul 2020 - **Published:** 30 Jul 2020

Keywords: Amyand hernia, appendicitis, bassinet, kelotomy

Copyright: Mohammed Lamghari et al. PAMJ Clinical Medicine (ISSN: 2707-2797). This is an Open Access article distributed under the terms of the Creative Commons Attribution International 4.0 License (<https://creativecommons.org/licenses/by/4.0/>), which permits unrestricted use, distribution, and reproduction in any medium, provided the original work is properly cited.

Cite this article: Mohammed Lamghari et al. Amyand hernia with acute appendicitis: an exceptional case report. PAMJ Clinical Medicine. 2020;3(150). 10.11604/pamj-cm.2020.3.150.24332

Available online at: <https://www.clinical-medicine.panafrican-med-journal.com//content/article/3/150/full>

Amyand hernia with acute appendicitis: an exceptional case report

Mohammed Lamghari^{1,&}, Mohamed Bouzroud¹

¹Department of General Surgery, Military Hospital Mohammed V (HMIMV), Faculty of Medicine and Pharmacy, Mohammed V University, Rabat, Morocco

&Corresponding author

Mohammed Lamghari, Department of General Surgery, Military Hospital Mohammed V (HMIMV), Faculty of Medicine and Pharmacy, Mohammed V University, Rabat, Morocco

Image in medicine

A 45 year old male patient, was admitted to the emergency department of our hospital with acute pain over the right inguinal region. Physical examination founded an irreducible and painful right inguinal hernia. The patient has been put in condition and he was brought to the operating theatre for emergency surgery. Surgical exploration by kelotomy revealed the presence of acute appendicitis (A) in a hernia sac corresponding to Amyand's hernia (B). An appendectomy was preformed, and the hernia defected was closed by the technique of Bassinet. The patient recovered well and left the hospital two days after. The histological examination of the appendix confirmed the diagnosis of acute appendicitis.

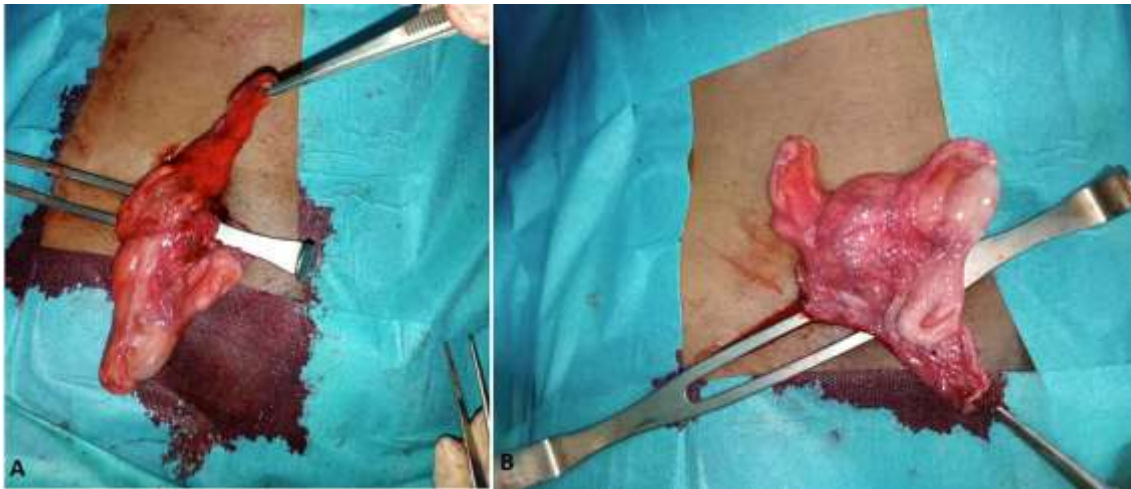


Figure 1: A) operative view of the appendicitis after kelotomy: B) image showing Amyand hernia