

Images in clinical medicine



A rare case of a floating left atrial myxoma as an incidental finding in an asymptomatic patient

Abdelmajid El Adaoui, Rime Benmalek

Corresponding author: Rime Benmalek, Resident in Department of cardiology, Hospital University Center Ibn Rochd, Casablanca, Morocco. Rime.benmalek@gmail.com

Received: 16 Jun 2020 - **Accepted:** 03 Jul 2020 - **Published:** 07 Jul 2020

Keywords: Floating left atrial myxoma, asymptomatic, surgery

Copyright: Abdelmajid El Adaoui et al. PAMJ Clinical Medicine (ISSN: 2707-2797). This is an Open Access article distributed under the terms of the Creative Commons Attribution International 4.0 License (<https://creativecommons.org/licenses/by/4.0/>), which permits unrestricted use, distribution, and reproduction in any medium, provided the original work is properly cited.

Cite this article: Abdelmajid El Adaoui et al. A rare case of a floating left atrial myxoma as an incidental finding in an asymptomatic patient. PAMJ Clinical Medicine. 2020;3(91). 10.11604/pamj-cm.2020.3.91.24356

Available online at: <https://www.clinical-medicine.panafrican-med-journal.com//content/article/3/91/full>

A rare case of a floating left atrial myxoma as an incidental finding in an asymptomatic patient

Abdelmajid El Adaoui^{1,&}, Rime Benmalek¹

¹Department of cardiology, Hospital University Center Ibn Rochd, Casablanca, Morocco

&Corresponding author

Rime Benmalek, Department of cardiology, Hospital University Center Ibn Rochd, Casablanca, Morocco

Image in medicine

We report the case of a 63-year-old female with history of hypertension, who presented to our echocardiography laboratory to undertake preoperative cardiac ultrasound before undergoing cholecystectomy. In her medical history, the patient complained from episodes of palpitations for 1 month, with no stroke or embolic event. Physical examination was normal. Electrocardiogram showed atrial fibrillation (AF) that was never discovered before. Transthoracic Echocardiography (TEE) revealed a large round mass freely floating in a dilated left atrium (LA) measuring 24x20, with no attachment to the interatrial septum. The mass was not very mobile and didn't prolapse in the left ventricle, and

wasn't obstructive (mean gradient = 4mmHg), only a mild mitral regurgitation was found (A,B). Considering the presence of AF in addition to the mass free-floating movement in the LA, we concluded that it was more likely a thrombus, rather than a cardiac tumour. Thus, antithrombotic therapy with heparin was initiated. After 1 month of treatment, the mass remained unchanged with no reduction of its size, the diagnosis was then reconsidered. We performed a Computed Tomography Angiography (CTA) that

found a left atrial hypointense mass with no other thrombi elsewhere. The patient underwent surgery, and a large smooth spherical pink colored mass was removed, compatible with a diagnosis of cardiac tumor. It was then confirmed by anatomopathological examination that it was an atrial myxoma. The postoperative follow-up was uneventful and the patient was discharged from the hospital with no sign or residual tumor in the control TEE.

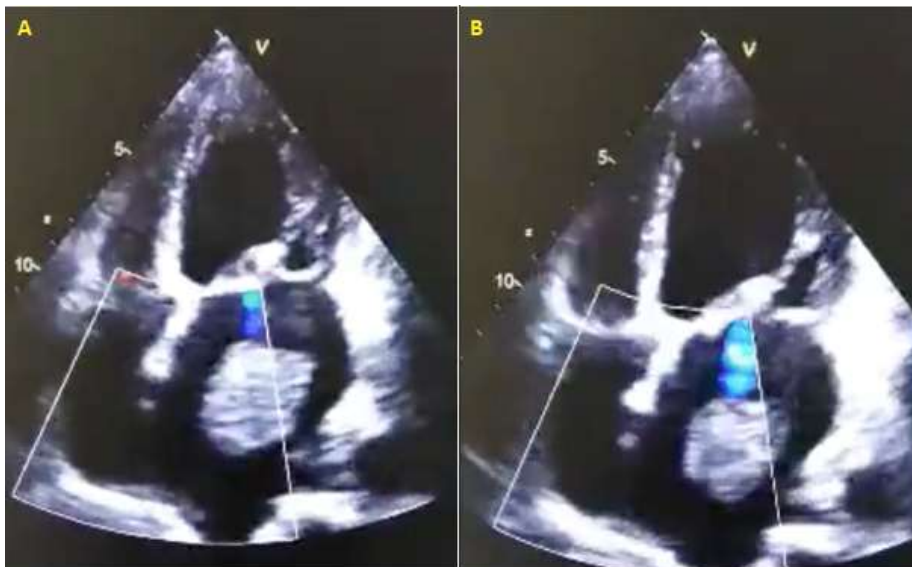


Figure 1: (A,B) transthoracic echocardiography showing a large round mass free-floating in a dilated left atrium with no attachments to the interatrial septum, associated to a mild mitral regurgitation