

Images in clinical medicine



Electrocardiogram (ECG) changes of a patient with severe hyperkalemia

Sarvesh Seger^{1,&}

Corresponding author: Sarvesh Seger, School of Medicine, International Medical University, Clinical Campus Kluang, Kluang, Johor, Malaysia. sars2509@gmail.com

Received: 01 Dec 2020 - **Accepted:** 08 Feb 2021 - **Published:** 09 Feb 2021

Keywords: Hyperkalemia, electrocardiogram, emergency, Brugada, end stage renal disease

Copyright: Sarvesh Seger et al. PAMJ Clinical Medicine (ISSN: 2707-2797). This is an Open Access article distributed under the terms of the Creative Commons Attribution International 4.0 License (<https://creativecommons.org/licenses/by/4.0/>), which permits unrestricted use, distribution, and reproduction in any medium, provided the original work is properly cited.

Cite this article: Sarvesh Seger et al. Electrocardiogram (ECG) changes of a patient with severe hyperkalemia. PAMJ Clinical Medicine. 2021;5(55). 10.11604/pamj-cm.2021.5.55.27254

Available online at: <https://www.clinical-medicine.panafrican-med-journal.com//content/article/5/55/full>

Electrocardiogram (ECG) changes of a patient with severe hyperkalemia

Sarvesh Seger^{1,&}

¹School of Medicine, International Medical University, Clinical Campus Kluang, Kluang, Johor, Malaysia

&Corresponding author

Sarvesh Seger, School of Medicine, International Medical University, Clinical Campus Kluang, Kluang, Johor, Malaysia

Image in medicine

A 55-year-old gentleman with underlying type 2 diabetes mellitus, dyslipidemia, hypertension, and end stage renal disease presented with shortness of breath, vomiting and worsening fatigue for one day after missing his scheduled hemodialysis. Physical examination in revealed tachypnoea with a respiratory rate of 30 breaths per minute, and fine mid inspiratory crepitations at the lung bases. Initial blood investigations in the emergency department revealed severe metabolic acidosis and hyperkalemia with a potassium of 7.6 mmol/L. A 12 lead electrocardiogram was done and several features that suggest hyperkalemia were detected such as a narrow based and symmetrical tall, tented T wave. In V1 the QRS complex is

reminiscent of Brugada type 1 which is probably Brugada phenocopy and are often seen in hyperkalemia. There is ST elevation in V2, a single precordial lead. There is no reciprocal ST depression, and a lone ST elevation does not indicate ischemia. This may be caused by hyperkalemia as well. There is a broad QRS of 136ms, widened QRS is characteristic of hyperkalemia. There is a broad P wave and the PR interval is approximately 200ms. Left ventricular

hypertrophy is also present. Due to impending respiratory collapse, he was subsequently intubated. His hyperkalemia was treated with intravenous short acting human insulin, dextrose 50%, calcium gluconate, sodium bicarbonate and calcium polystyrene sulfonate. He was subsequently admitted to the intensive care unit (ICU) and had undergone emergency hemodialysis.

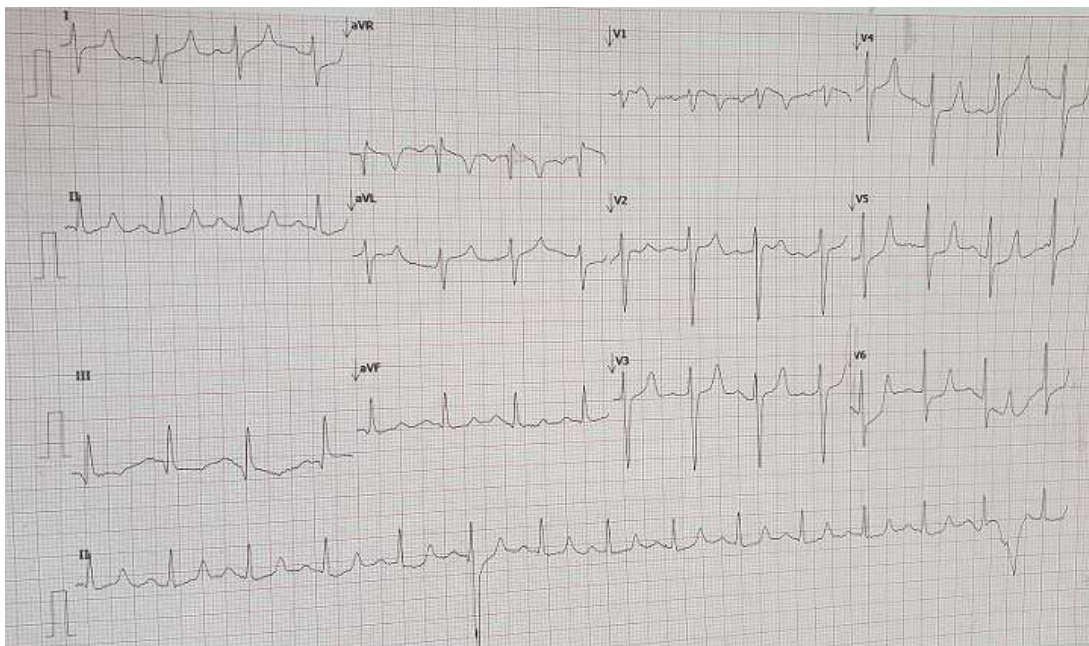


Figure 1: electrocardiogram changes of a patient with severe hyperkalemia showing narrow based and symmetrical tall, tented T waves. The QRS complex is reminiscent of Brugada type 1 in lead V1. There is wide QRS complex of 136ms, a broad P wave and the PR interval is approximately 200ms