

## Images in clinical medicine



## Suspended Morgagnian nucleus

 Karima Madbouhi,  Lalla Ouafae Cherkaoui

**Corresponding author:** Karima Madbouhi, Université Mohammed V Souissi, Ophtalmologie A, Hôpital des Spécialités, Centre Hospitalier Universitaire Rabat, Rabat, Morocco. karima.madbouhi@gmail.com

**Received:** 18 Jul 2021 - **Accepted:** 25 Jul 2021 - **Published:** 26 Jul 2021

**Keywords:** Morgagnian cataract, nucleus, cortex

**Copyright:** Karima Madbouhi et al. PAMJ Clinical Medicine (ISSN: 2707-2797). This is an Open Access article distributed under the terms of the Creative Commons Attribution International 4.0 License (<https://creativecommons.org/licenses/by/4.0/>), which permits unrestricted use, distribution, and reproduction in any medium, provided the original work is properly cited.

**Cite this article:** Karima Madbouhi et al. Suspended Morgagnian nucleus. PAMJ Clinical Medicine. 2021;6(30). 10.11604/pamj-cm.2021.6.30.30845

**Available online at:** <https://www.clinical-medicine.panafrican-med-journal.com//content/article/6/30/full>

## Suspended Morgagnian nucleus

Karima Madbouhi<sup>1,&</sup>, Lalla Ouafae Cherkaoui<sup>1</sup>

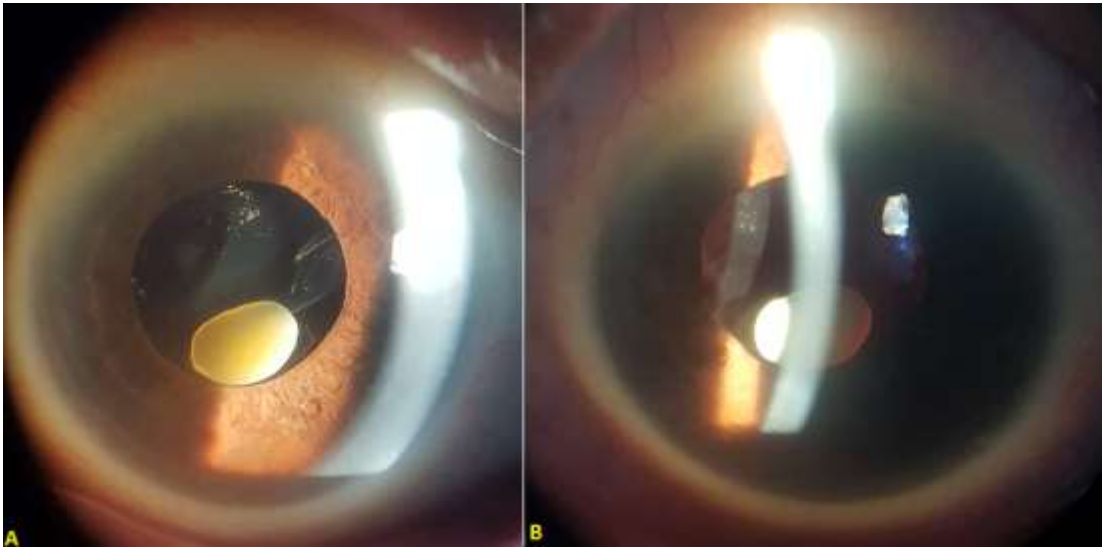
<sup>1</sup>Université Mohammed V Souissi, Ophtalmologie A, Hôpital des Spécialités, Centre Hospitalier Universitaire Rabat, Rabat, Morocco

**&Corresponding author**

Karima Madbouhi, Université Mohammed V Souissi, Ophtalmologie A, Hôpital des Spécialités, Centre Hospitalier Universitaire Rabat, Rabat, Morocco

## Image in medicine

Morgagnian cataract is a cataract in which there is liquefaction of the cortex and sinking of the dense nucleus in the capsular bag. In some cases, liquified cortical matter gets completely resorbed leaving behind just the transparent lens capsule superiorly and the dense nucleus in the bag inferiorly. We report the case of a 70-year-old patient, with no history of ocular trauma, presented with diminution of vision in the right eye for 1 year. Slit lamp examination showed a small cataract nucleus, suspended in the anterior chamber by the vitreous after spontaneous rupture of the capsular bag in the inf-nasal area and resorption of the cortex (A,B). She underwent an anterior nucleus extraction followed by an anterior vitrectomy and implantation of an iris fixation lens.



**Figure 1:** (A,B) image of the anterior segment, showing a small cataract nucleus, suspended in the anterior chamber by the vitreous after spontaneous rupture of the capsular bag in the inf-nasal area and resorption of the cortex